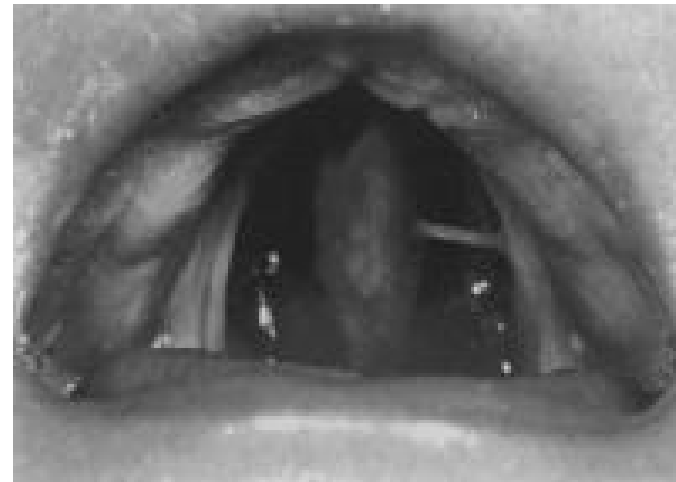


# CLEFT LIP AND PALATE

# Introduction

- ▶ Facial clefting is the second most common congenital deformity (after clubfoot).
- ▶ Affects 1 in 750 births
- ▶ Problems are cosmetic, dental, speech, swallowing, hearing, facial growth, emotional



# Epidemiology

- ▶ Cleft Lip +/- Palate- 2 Male: 1 Female
- ▶ Cleft Palate - 2 Female: 1 Male
- ▶ Cleft Lip +/- Palate- Native Americans > Oriental and Caucasians > Blacks
- ▶ Cleft Palate- Same among ethnic groups
- ▶ Environmental: Ethanol, Rubella virus, thalidomide, aminopterin

# Epidemiology

- ▶ Increased Clefts with maternal diabetes mellitus and amniotic band syndrome
- ▶ Increased Clefts with increased paternal age
- ▶ Cleft Lip + Palate– 50%
- ▶ Cleft Palate– 30%
- ▶ Cleft Lip– 20%
- ▶ Cleft Lip + Alveolus– 5%

# Embryology

- ▶ Primary Palate– Triangular area of hard palate anterior to incisive foramen to point just lateral to lateral incisor teeth
  - Includes that portion of alveolar ridge and four incisor teeth.
- ▶ Secondary Palate– Remaining hard palate and all of soft palate



# Embryology

## ▶ Secondary Palate

- Forms in 6th to 9th weeks of gestation
- Palatal shelves change from vertical to horizontal position and fuse
- Tongue must migrate antero-inferiorly

# Anatomy

## ▶ Hard Palate

- Bones: Maxilla( Palatine Processes) + Palatine Bones(Horizontal Lamina)
- Blood Supply: Greater Palatine Artery
- Nerve Supply: Anterior Palatine Nerve

# Anatomy

## ▶ Soft Palate

- Fibromuscular shelf attached like a shelf to posterior portion of hard palate
- Tenses, elevates, contacts Passavant's Ridge
- Muscles: Tensor Veli Palatini(CNV), Levator Veli Palatini(Primary Elevator), Musculus Uvulae, Palatoglossus, Palatopharyngeus(CN IX and X)

# Genetics

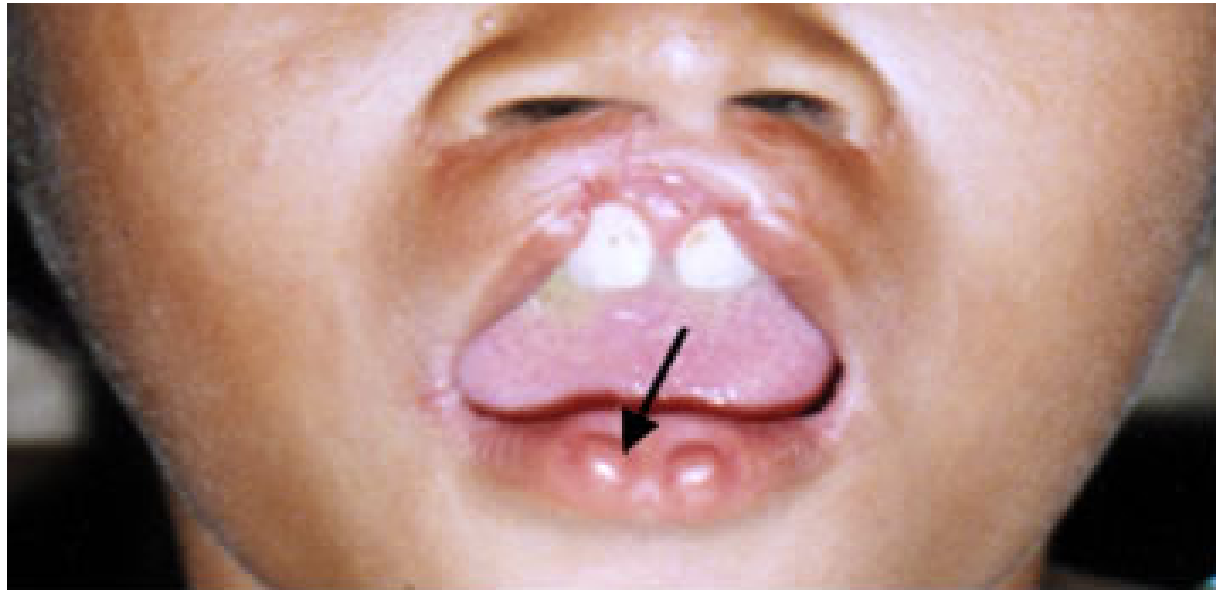- ▶ Non-syndromic inheritance is multifactorial
  - Cleft Lip, With or Without Cleft Palate:
    - One Parent-2%
    - One Sibling- 4%      Two Siblings- 9%
    - One Parent + One Sibling- 15%
  - Cleft Palate:
    - One Parent- 7%
    - One Sibling- 2%      Two Siblings- 1%
    - One Parent + One Sibling- 17%

# Genetics

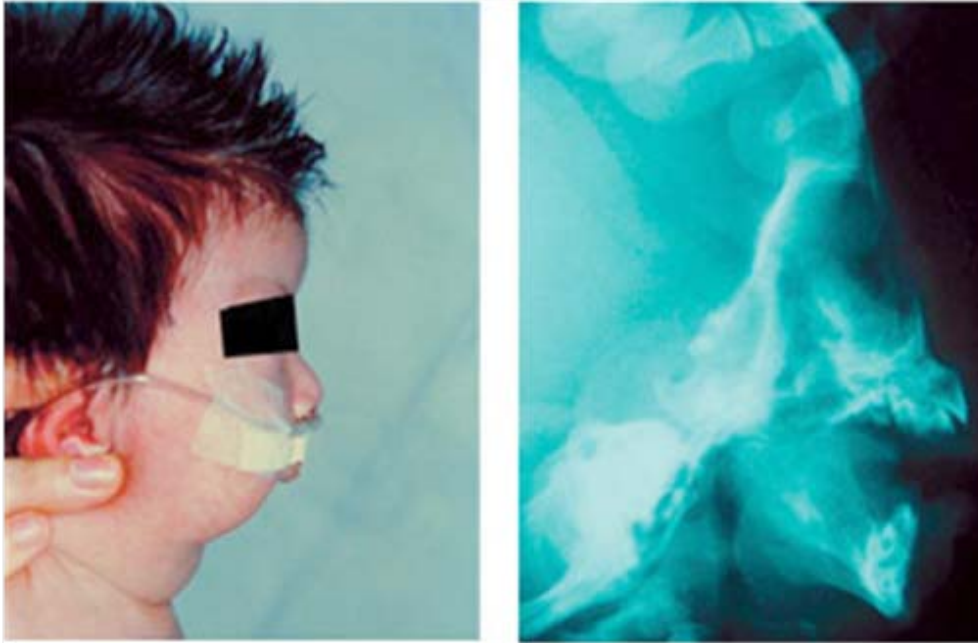
- ▶ Increased clefts with chromosome aberrations
- ▶ Clefts a part of a Syndrome 15–60% of time
- ▶ More than 200 syndromes include clefts
- ▶ Cleft Palate– Apert's, Stickler's, Treacher
- ▶ Cleft Lip +/- Palate– Van der Woude's, Waardenberg's

# Syndromes

- ▶ van der Woude syndrome – Autosomal dominant disorder is on chromosome



# Syndromes



## Robin Sequence

- ▶ Micrognathia
- ▶ Glossoptosis
- ▶ Cleft palate
- ▶ Associated abnormalities – 52% to 83%

# Syndromes

## Velocardiofacial syndrome

- ▶ Overlaps with DiGeorge syndrome and conotruncal anomaly face syndrome
- ▶ CATCH 22: cardiac anomalies (usually conotruncal), *ab*normal facies, *th*ymic disorders, *d*eft palate, and *h*ypocalcemia caused a deletion of chromosome 22 at the q11.2 region.

# Syndromes

## Stickler syndrome

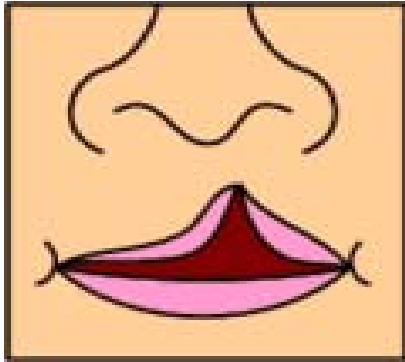- ▶ Most common syndrome found in children with Robin Sequence – 14% to 34% of cases
- ▶ Sensorineural hearing loss
- ▶ Myopia – Risk of retinal detachment and early cataracts
- ▶ Hypermobility of joints
- ▶ Stiffness and premature osteoarthritis

# Cleft Formation

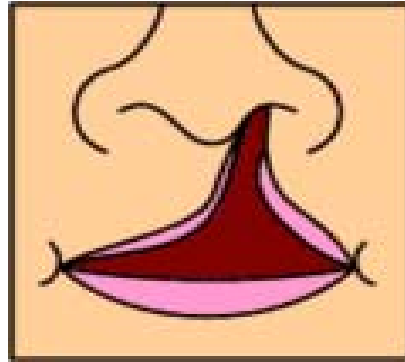
- ▶ Cleft result in a deficiency of tissue
- ▶ Cleft lip occurs when an epithelial bridge fails
- ▶ Clefts of primary palate occur anterior to incisive foramen
- ▶ Clefts of secondary palate occur posterior to incisive foramen

# Cleft Formation

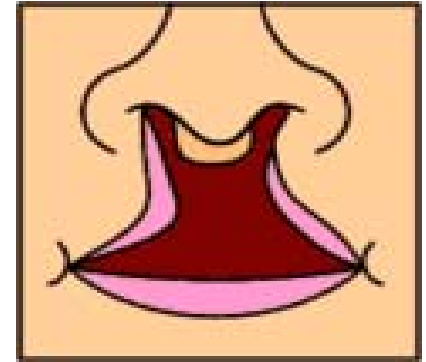
- ▶ Secondary Palate closes 1 week later in females
- ▶ Cleft of lip increases likelihood of cleft of palate because tongue gets trapped.



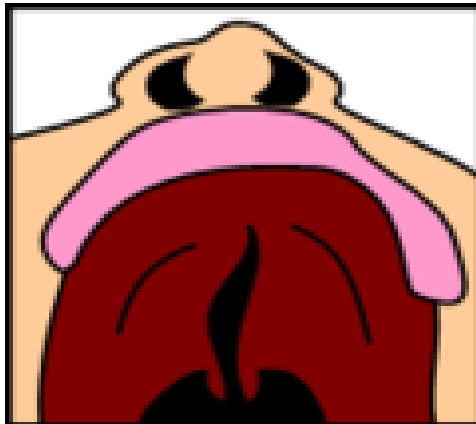
UNILATERAL INCOMPLETE



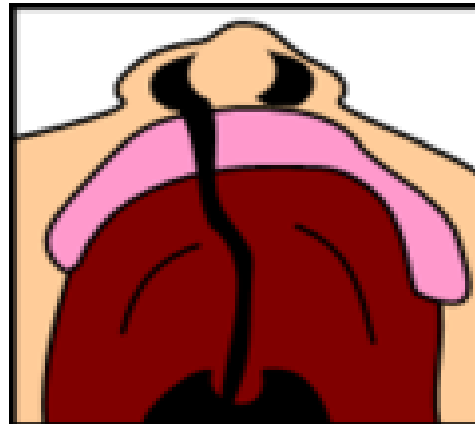
UNILATERAL COMPLETE



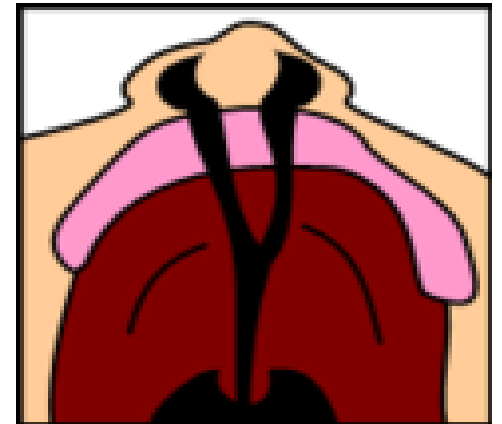
BILATERAL COMPLETE



INCOMPLETE CLEFT PALATE

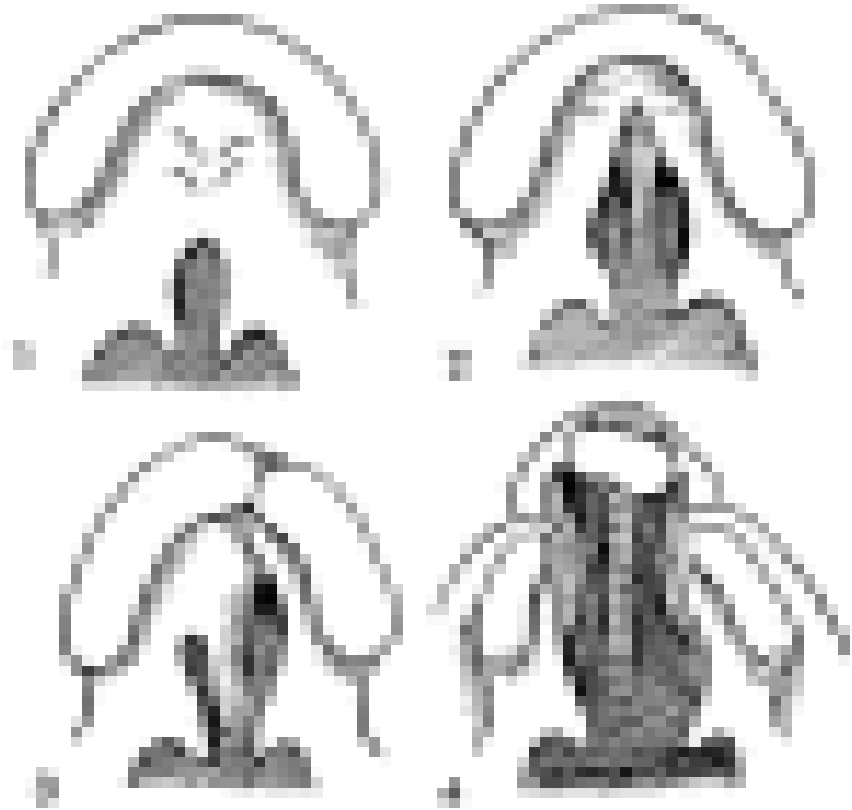


UNILATERAL COMPLETE LIP AND  
PALATE



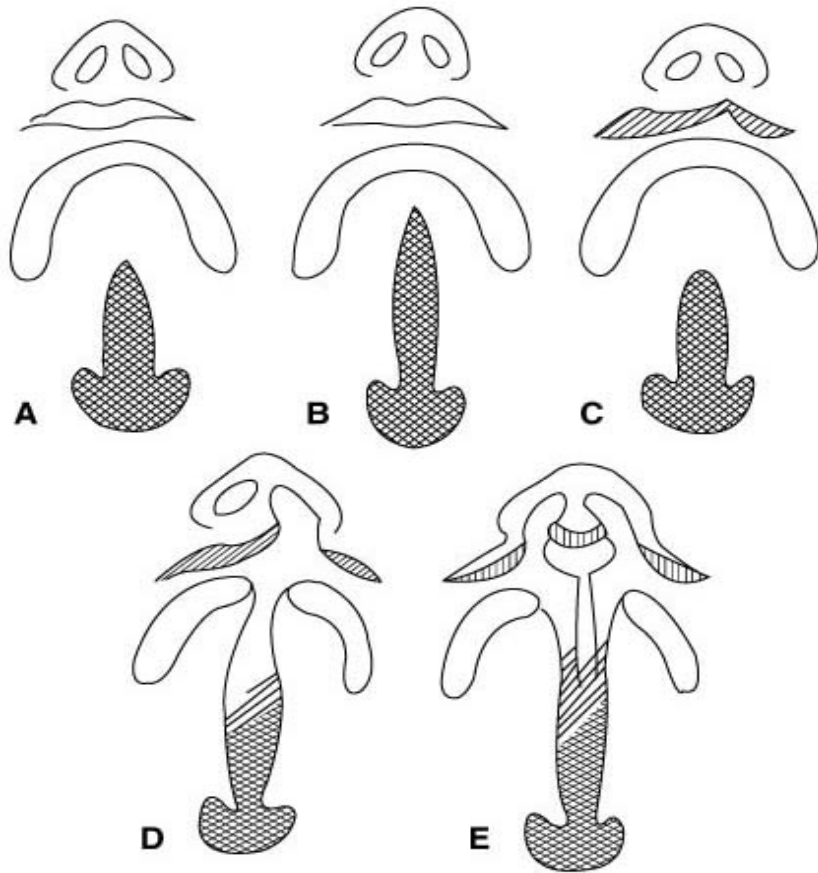
BILATERAL COMPLETE

# Classification – Veau



- ▶ Clefts of soft palate only
- ▶ Clefts of soft and hard palate reaching anteriorly to incisive foramen
- ▶ Complete unilateral alveolar clefts – generally involve the lip as well
- ▶ Bilateral alveolar clefts – associated with bilateral clefts of the lip

# Classification



- ▶ A – Incomplete cleft of the secondary palate
- ▶ B – Complete cleft of the secondary palate
- ▶ C – Incomplete cleft of the primary and secondary palates
- ▶ D – Unilateral complete cleft of the primary and secondary palates
- ▶ E – Bilateral complete cleft of the primary and secondary palates


# Unilateral Cleft Lip

- ▶ Nasal floor communicates with oral cavity
- ▶ Maxilla on cleft side is hypoplastic
- ▶ Columella is displaced to normal side
- ▶ Nasal ala on cleft side is laterally, posteriorly, and inferiorly displaced
- ▶ Lower lat on cleft side –lower, more obtuse
- ▶ Lip muscles insert into ala and columella


# Palatal Clefts

- ▶ Soft palate muscles insert on posterior margin of remaining hard palate rather than midline raphe.
- ▶ Associated Dental Abnormalities
  - Supernumery Teeth– 20%
  - Dystrophic Teeth– 30%
  - Missing Teeth– 50%
  - Malocclusion– 100%


# Management

- ▶ Team Approach
  - ▶ Initial Head and Neck Examination
  - ▶ Speech Disorders
  - ▶ Ear Disease
  - ▶ Airway Problems
  - ▶ Surgical Repair
- 

# Head and Neck Exam

- ▶ Head– facial symmetry
  - ▶ Otologic– auricle and canal development and location, pneumatic otoscopy, forks
  - ▶ Rhinoscopy– identifies clefting, septal anomalies, masses, choanal atresia
  - ▶ Oral Exam– cleft, dental, tongue
  - ▶ Upper airway– phonation, cough, swallow
- 

# Speech Disorders

- ▶ Errors in Articulation: Fricatives, Affricates
  - ▶ Velopharyngeal Competence– Most important determinant of speech quality in cleft palate patients–75% achieve competence after initial palate surgery
  - ▶ Incompetence– nasal emission or snort
  - ▶ Evaluation– Direct exam , Fiberoptic Exam
- 

# Ear Disease

- ▶ Cleft Lip– Incidence similar to normal pop.
- ▶ Cleft Palate– Almost all with ETD, CHL
- ▶ ETD– Due to abnormal insertion of levator veli palatini and tensor veli palatini into posterior hard palate
- ▶ ETD– Returns to normal by mid–adolescent
- ▶ Cleft Palate– Increased Cholesteatoma(7%)

# Ear Disease


- ▶ **Otologic Goals For Cleft Palate Patients**
  - Adequate hearing
  - Ossicular chain continuity
  - Adequate middle ear space
  - Prevent TM deterioration
- ▶ **Indications for Myringotomy Tubes**
  - CHL, Persistent/Recurrent effusion, Retraction
  - Cleft palate: Multiple BMTs from 3mo. – 12 yrs

# Airway Problems


- ▶ More common in Cleft Palate patients with concomitant structural or functional anomalies.
- ▶ e.g. Pierre–Robin Sequence
  - Micrognathia, Cleft Palate, Glossoptosis
  - May develop airway distress from tongue becoming lodged in palatal defect

# Surgical Repair– Cleft Lip

## ▶ Lip Adhesions–

- 2 weeks of age
  - Converts complete cleft into incomplete cleft
  - Serves as temporizing measure for those with feeding problems
  - May interfere with definitive lip repair
  - Less often needed in recent years due to wider variety of specialty feeding nipples
- 

# Surgical Repair– Cleft Lip

- ▶ Cleft lip repaired at 10 weeks
  - ▶ Rotation–advancement method– Most common in the U.S.
  - ▶ Nine Landmarks
  - ▶ Rotation Flap cuts made first
  - ▶ Advancement cuts made next
  - ▶ Cleft side nasal ala cuts made last
- 

# Cleft Lip Repair

## Rule of 10's

- ▶ Surgery > 10 weeks old
- ▶ Weight > 10 pounds
- ▶ Hemoglobin level > 10 g/dL

# Cleft Lip Repair

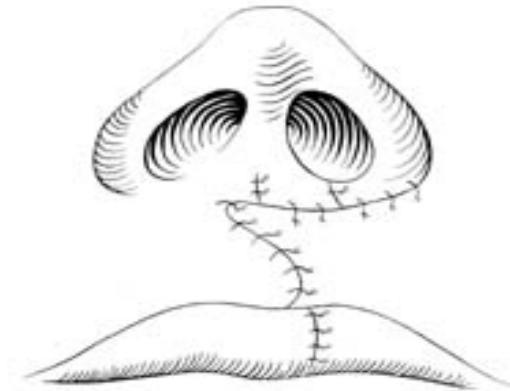
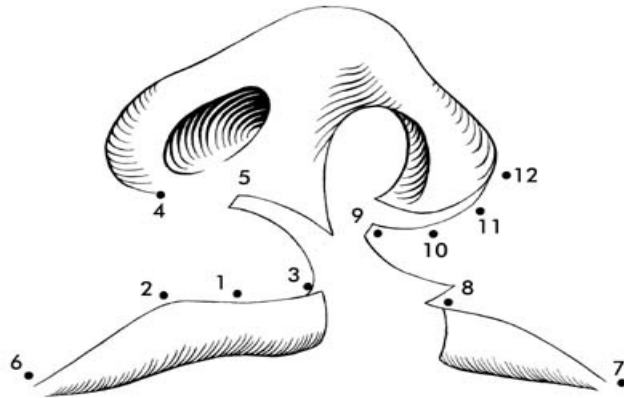
## Goals

- ▶ Bridge the cleft
- ▶ Create a complete muscular sling around the entire circumference of the oral cavity
- ▶ Approximate cleft edges
- ▶ Maintain Cupid's bow and philtral dimple
- ▶ Align vermillion border
- ▶ Create an intact nasal floor and sill
- ▶ Produce symmetry of the alar base and columella
- ▶ Reconstituting the circumferential integrity of the orbicularis oris muscle

# Cleft Lip Repair – Types

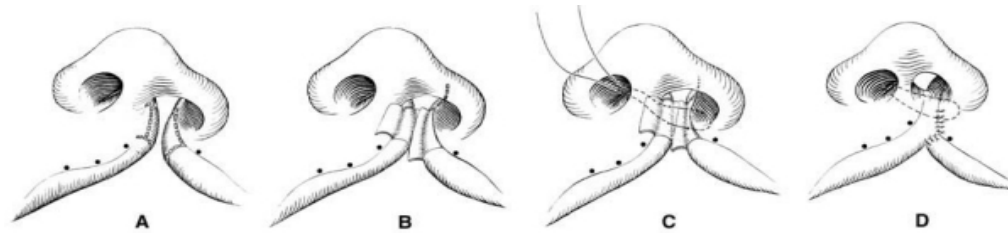
- ▶ Millard Repair – Rotation advancement technique
- ▶ Randall – Graham – Triangular flap interposition
- ▶ Rose – Thompson – Straight line repair, Risk of vertical contracture

# Millard Repair

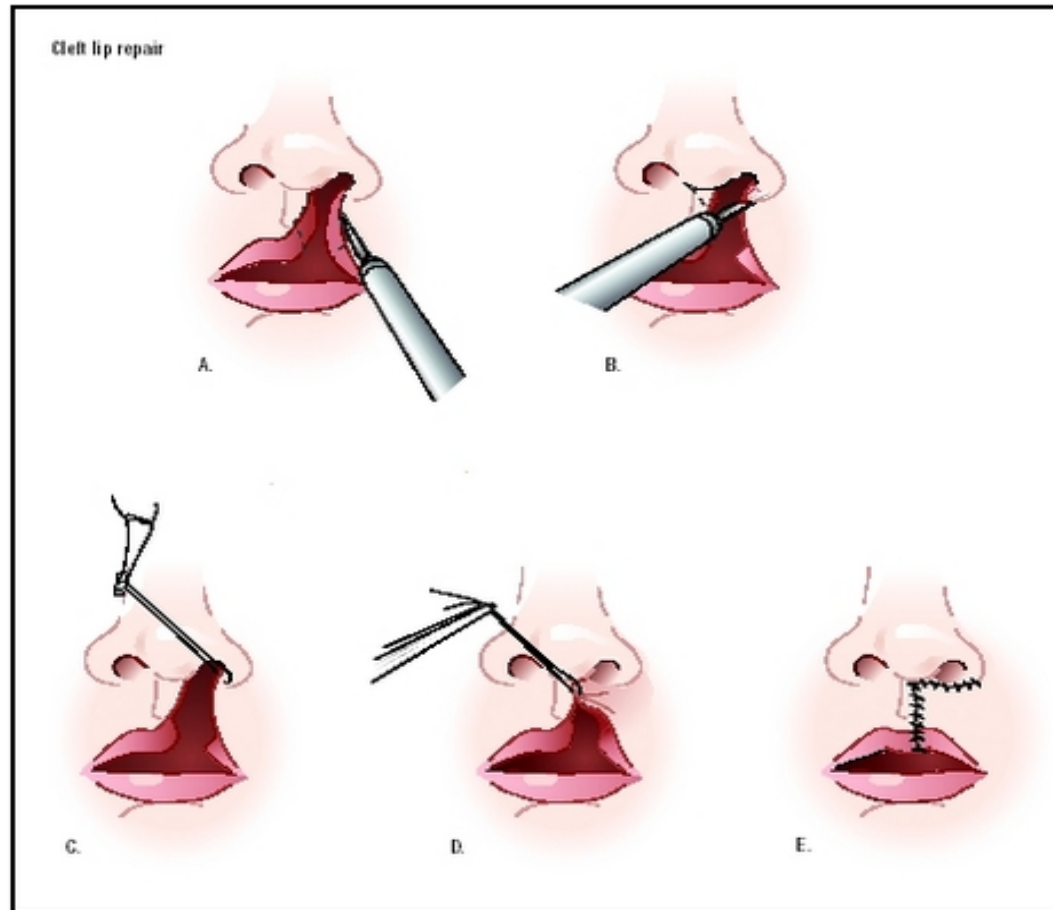


- ▶ Downward and lateral rotation of the medial segment of the cleft lip combined with the medial advancement of the lateral cleft segment into the defect
- ▶ Bridges the gap
- ▶ Maintains the rotation flap in position
- ▶ Maintains the amount of vertical height gained by the rotation flap and back cut

# Seibert's Technique Lip Adhesion



- ▶ Medially and laterally based rectangular flaps from the margin of the cleft
- ▶ Tension-bearing suture through the membranous septum.
- ▶ Unilateral lip adhesion: **A**, landmarks and incisions; **B**, flaps elevated and undermined; **C**, placement of 3-0 nylon retention suture; **D**, final suturing.




Cleft lip repair. The edges of the cleft between the lip and nose are cut (A and B). The bottom of the nostril is formed with suture (C). The upper part of the lip tissue is closed (D), and the stitches are extended down to close the opening entirely (E).

# Cleft Palate Repair – Timing

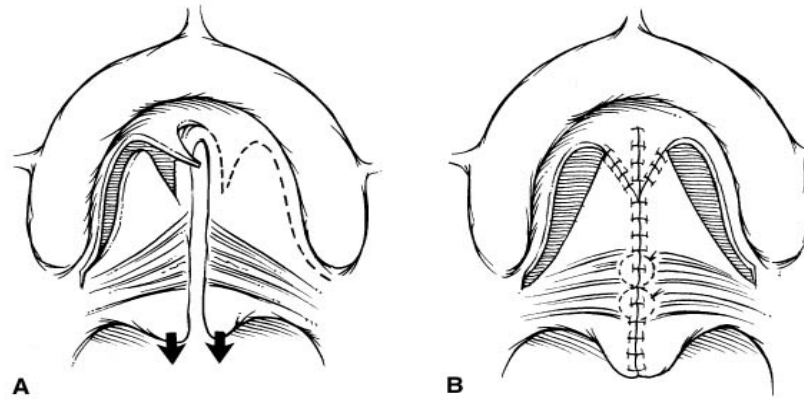
- ▶ Dorf and Curtin
  - 10% occurrence of articulation errors when palatoplasty was completed by 1 year
  - 86% incidence of articulation errors when repair was complete after 1 year
- ▶ Haapanen and Rantala – Significantly fewer children in the groups repaired before 18 months had hypernasal speech, articulation errors, or required secondary surgery to correct speech

# Cleft Palate Repair

- ▶ V-Y Pushback
  - ▶ Two Flap Palatoplasty
  - ▶ Four Flap Palatoplasty
  - ▶ Schweckendick's Primary Veloplasty
  - ▶ Furlow Palatoplasty
- 

# Cleft Palate Repair

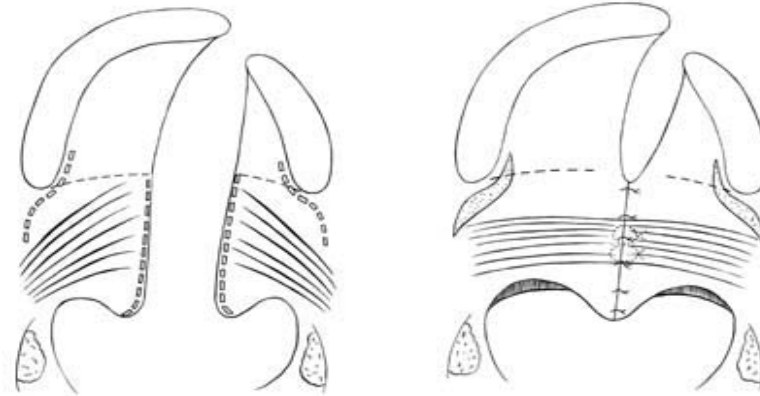
## V-Y Pushback



- ▶ Two uni-pedicled flaps (greater palatine artery) and one or two anteriorly based pedicled flaps
- ▶ Posterior flaps rotated in a V-Y advancement technique – increasing the length of the palate
- ▶ Nasal mucosa not closed
- ▶ Improved speech results compared with bipedicled techniques
- ▶ Indicated for incomplete clefts

# Cleft Palate Repair

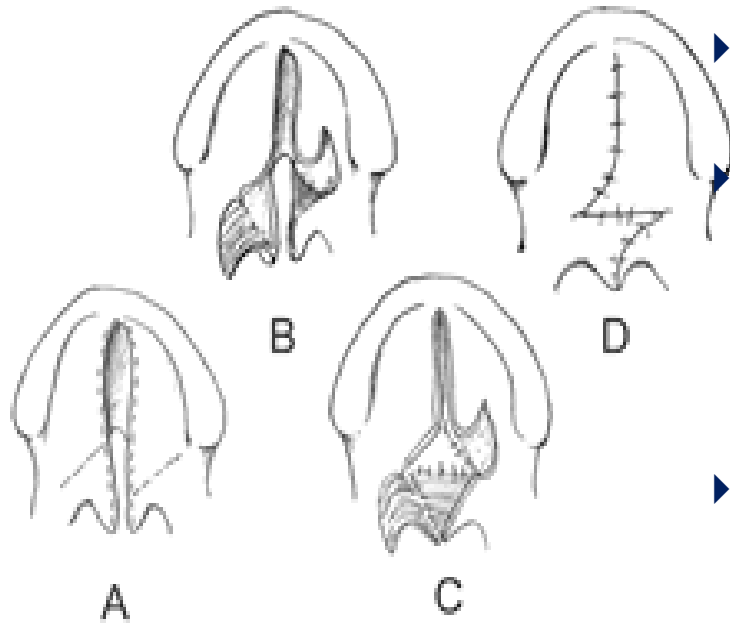
## Schweckendick's Primary Veloplasty



- ▶ Incisions made in soft palate
- ▶ Muscle bundles released from the posterior hard palate and rotated
- ▶ Reconstruction of levator sling
- ▶ Closure of mucosal layers separately

# Cleft Palate Repair

## Furlow Palatoplasty



- ▶ Lengthens the soft palate
- ▶ Reconstructs the muscle sling.
- ▶ Also commonly used to correct velopharyngeal insufficiency in patients with submucous cleft palate
- ▶ Speech outcomes are improved compared with other palatoplasty techniques.

# Cleft Palate Repair

## Complications

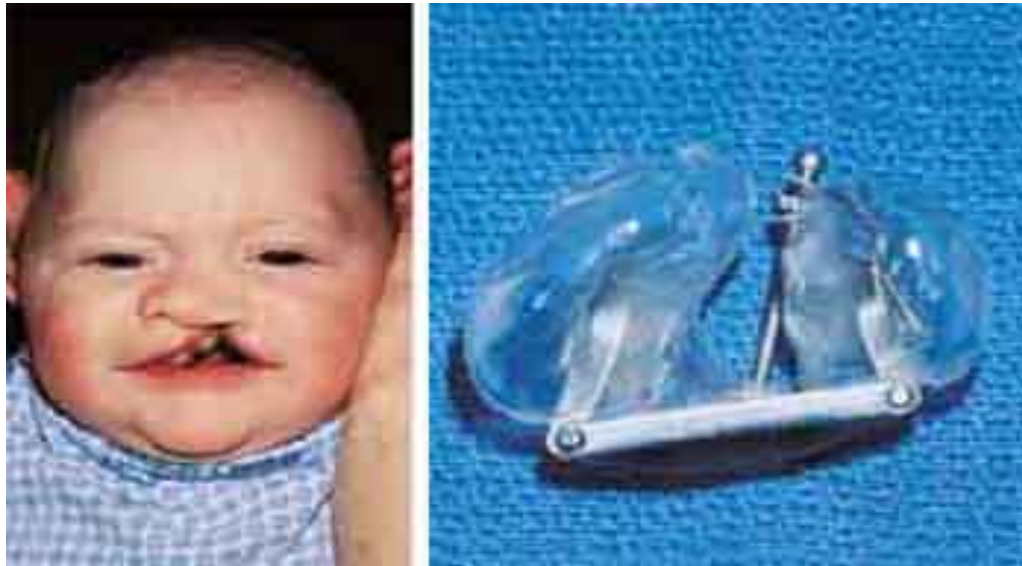- ▶ Oronasal fistula – 8.7% to 23%
  - Sites of fistulization are typically the anterior hard palate and the junction of the hard and soft palate.
- ▶ Velopharyngeal insufficiency

# Non-Surgical Treatment

## ▶ Dental Obturator

- For high-risk patients or those that refuse surgery.
- Advantage– High rate of closure
- Disadvantage– Need to wear a prosthesis, and need to modify prosthesis as child grows.

# Latham Appliance



# Postnatal Management

- ▶ The Care will entail attention, not only to surgical repair, but also more immediate needs such as feeding.
- ▶ Primary lip repairs can often be undertaken at three months of age with palatal repairs around six months.
- ▶ Additional surgeries as well as speech and orthodontic therapies are often needed.
- ▶ The cleft Lip and Palate Association ([www.clapa.com/](http://www.clapa.com/)) provides support and information for parents.

# Feedings

- ▶ Infants with CL/P have few feeding problems.
- ▶ If the cleft involves the hard palate, the infant is usually not able to suck efficiently.
  - Experiment (special nipples or alternate feeding positions)
- ▶ The infant should be held in a nearly sitting position during feeding
  - Prevents flowing to the back into the nose.
- ▶ Should be burped frequently, (q 3–4min).

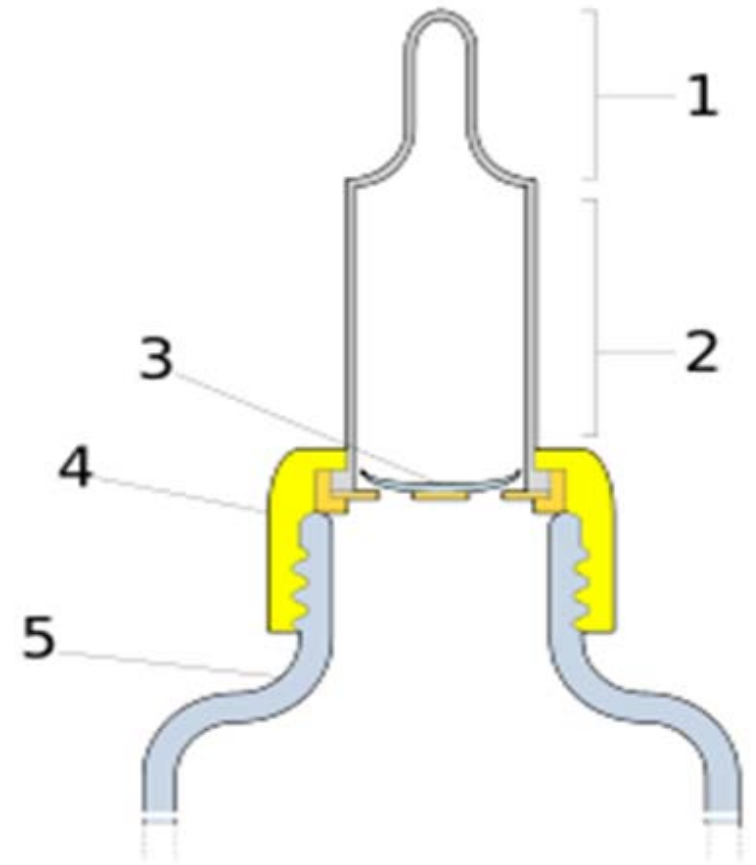
# Feedings

- ▶ It is important to keep the cleft clean
- ▶ Breastfeeding is extremely challenging.




# Haberman Feeder


- ▶ Activated by tongue and gum pressure.
- ▶ Milk cannot flow back.
- ▶ Replenished continuously as the baby feeds.
- ▶ Prevents the baby from being overwhelmed with milk.
- ▶ A gentle pumping action to the body of the nipple will increase flow.



# Family Care


- ▶ Have a family meeting with both parents present.
  - ▶ Infant should be brought to the parents as soon the mother and the infant are in satisfactory condition.
  - ▶ Allow the parents to observe, react and ask questions about the infant.
  - ▶ Explained the defect and the how the surgeon will most likely correct the clefts.
  - ▶ Before and after pictures are helpful.
- 

# Family Care

- ▶ Emphasize as possible to the parents the normal healthy features of the baby.
  - ▶ The baby should be present when the defect is explained, as ugly as the cleft might be.
  - ▶ Training the mother about feeding techniques and avoiding complications.
- 


# Timeline

## Five to Fifteen Months

- ▶ Monitor feeding, growth, and development
  - ▶ Repair cleft palate
  - ▶ Monitor ears and hearing
  - ▶ Instructions in oral hygiene
- 

# Timeline

Two to Five years old

- ▶ Monitor speech and language development
  - ▶ Manage velopharyngeal insufficiency
  - ▶ Monitor ears and hearing; ear tubes if indicated
  - ▶ Assess development and psychosocial needs
  - ▶ Consider lip/nose revision before school
- 

# Timeline

Six to Eleven years old

- ▶ Monitor speech and language; manage velopharyngeal insufficiency
  - ▶ Orthodontic evaluation and treatment
  - ▶ Alveolar bone graft
  - ▶ Monitor school and psychosocial needs
- 

# Timeline

Twelve to Twenty One years old

- ▶ Monitor school and psychosocial needs
- ▶ Orthodontics and restorative dentistry
- ▶ Genetic counseling
- ▶ Rhinoplasty (if needed)
- ▶ Orthognathic surgery (if needed)

# Famous People with Cleft Deformity

<b>Tom Brokaw</b>	American television journalist.
<b>Jesse Jackson</b>	Politician, professional civil rights activist and Baptist minister
<b>Peyton Manning</b>	NFL quarterback
<b>Annie Lennox</b>	Scottish pop musician and vocalist
<b>Mark Hamill</b>	Actor
<b>Tutankhamun</b>	Egyptian Pharaoh who may have had a cleft lip according to diagnostic imaging

# References

- ▶ Klaus & Fanaroff. *“Care of the high-risk neonate”*. Saunders”. 5<sup>th</sup> edition. 2001 USA.
- ▶ Colin D. Rudolph *“Rudolph’s Pediatrics”* McGraw–Hill. 21<sup>st</sup> edition. 2002. USA.
- ▶ Christensen, K, et al. “Cleft–twin sets in Finland 1948–1987”. *Cleft Palate Craniofac J* 1996; 33:530.
- ▶ Clementi, M, et al. “Evaluation of prenatal diagnosis of cleft lip with or without cleft palate and cleft palate by ultrasound: experience from 20 European registries”. EUROSCAN study group. *Prenat Diagn* 2000; 20:870.
- ▶ Milerad, J, et al. “Associated malformations in infants with cleft lip and palate: a prospective, population–based study”. *Pediatrics* 1997; 100:180.
- ▶ Cockell, A, Lees, M. “Prenatal diagnosis and management of orofacial clefts”. *Prenat Diagn* 2000; 20:149.